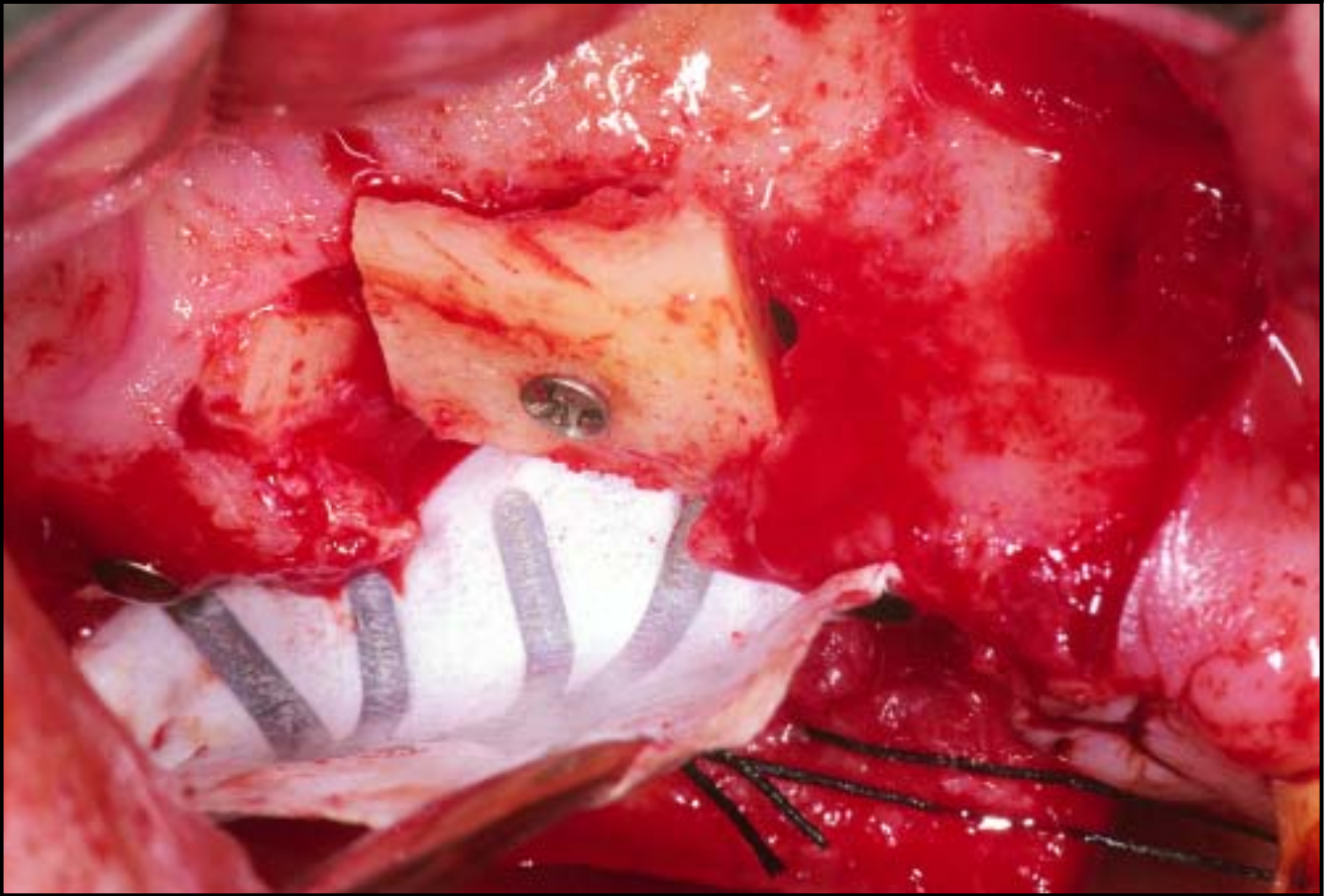
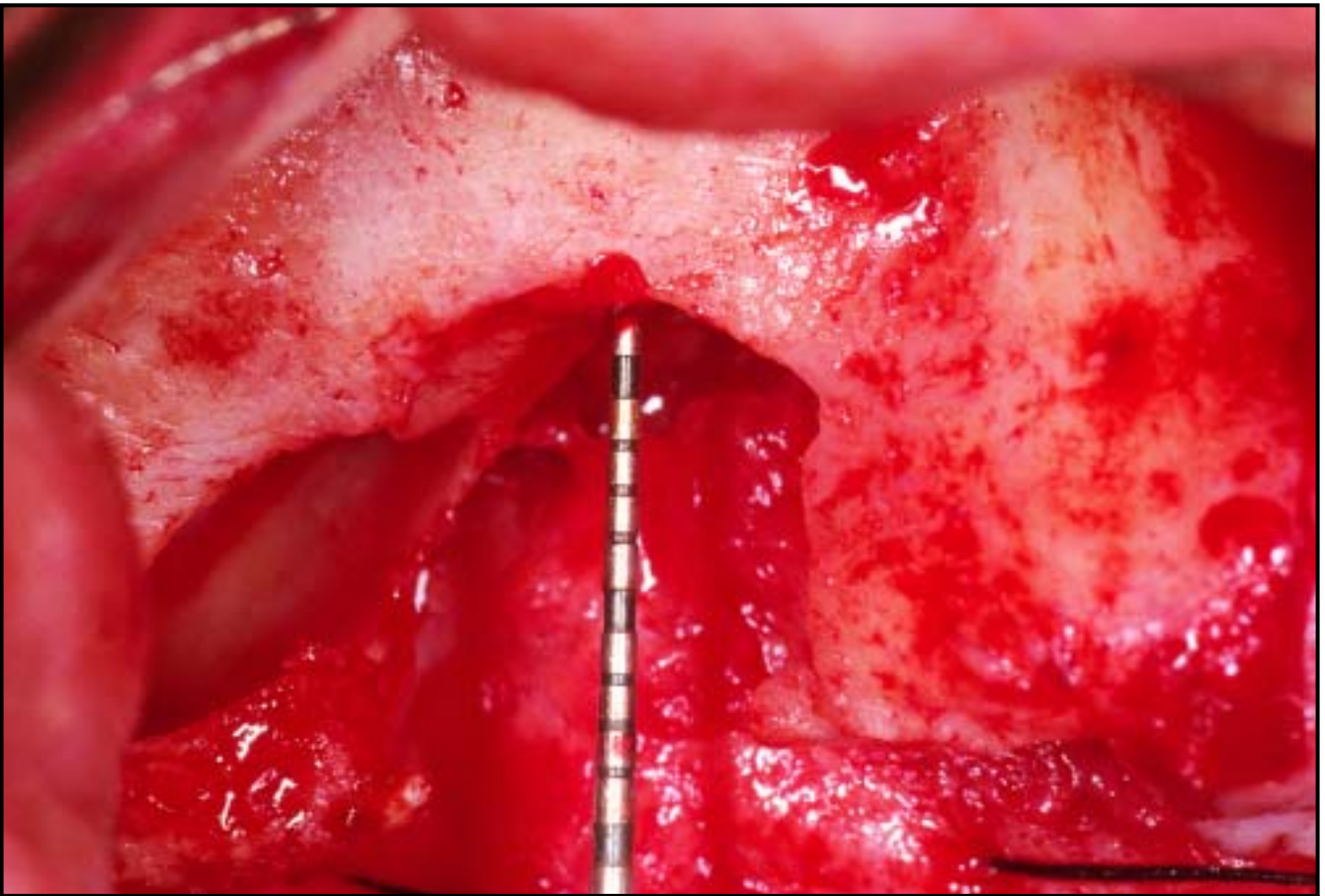
COPYRIGHT © 2004 BY QUINTESSENCE PUBLISHING CO, INC. PRINTING OF THIS DOCUMENT IS RESTRICTED TO PERSONAL USE ONLY. NO PART OF THIS ARTICLE MAY BE REPRODUCED OR TRANSMITTED IN ANY FORM WITHOUT WRITTEN PERMISSION FROM THE PUBLISHER.

Long-Term Evaluation of Osseointegrated Implants Placed in Sites Augmented with Sinus Floor Elevation Associated with Vertical Ridge Augmentation: A Retrospective Study of 38 Consecutive Implants with 1- to 7-Year Follow-up



Massimo Simion, MD, DDS*/Filippo Fontana, DDS**/
Giulio Rasperini, DDS***/Carlo Maiorana, MD, DDS*

This clinical study retrospectively evaluated, after 1 to 7 years of prosthetic loading, 38 implants consecutively placed in 16 surgical sites, where severe atrophy of the posterior maxilla was treated by combining sinus elevation with the vertical ridge regenerative procedure. Two different surgical techniques were adopted. In seven patients (16 implants), implants were placed at the same stage as the regenerative procedures. In the other seven patients (22 implants), implant placement was performed at second-stage surgery, after 6 to 13 months of submerged membrane healing. Each implant was classified as a success, survival, or failure. The distance between the top of the implant shoulder and the first visible bone-implant contact was assessed radiographically for every implant at the mesial and distal sides. Two membranes became exposed during the healing process (12.5%). In the remaining 14 sites (87.5%), the membrane remained covered for a 6- to 13-month healing period. The survival rate of the implants was 92.1%, whereas the success rate was 76.3%. Three implants (7.9%) failed. A comparison of the implant shoulder–bone-implant contact distances between abutment connection and the last examination showed a mean crestal loss of 1.65 mm at the mesial side and 1.68 mm at the distal side. The bone regenerated vertically by means of sinus floor elevation and vertical ridge augmentation showed the same biologic behavior as native, nonregenerated bone; however, in a few cases, its remodeling pattern seemed to determine slightly higher bone crest resorption. (Int J Periodontics Restorative Dent 2004;24:208–221.)

*Professor, Department of Periodontology and Implant Rehabilitation, University of Milan, School of Dentistry.

**Assistant Doctor, Department of Periodontology and Implant Rehabilitation, University of Milan, School of Dentistry.

***Consultant Professor, Department of Periodontology and Implant Rehabilitation, University of Milan, School of Dentistry.

Correspondence to: Dr Massimo Simion, Department of Periodontology and Implant Rehabilitation, University of Milan, School of Dentistry, Clinica Odontoiatrica e Stomatologica, Via della Commenda 10, 20129 Milano, Italy.

The use of osseointegrated implants in the treatment planning of maxillary posterior edentulous jaws has been well-documented.^{1,2} Since the first implant was used in dentistry, clinicians have had to carefully evaluate the available bone before planning an implant-supported rehabilitation. In the last few years, guided bone regeneration (GBR) and sinus elevation techniques have been shown to be effective for the placement of endosteal implants in severely resorbed maxillae. These surgical procedures have enormously expanded the possibility of successfully handling compromised patients with localized bone deficiencies of the maxilla; however, when posterior jaw atrophy is severe, a combination of the two techniques is needed.

Treatment planning depends on the anatomic features of the area to be treated; therefore, a classification of the defects of the posterior maxilla is advisable. Different classifications of partially edentulous patients have been suggested by several authors.^{3–5} Kennedy⁴ divided the partially edentulous spaces into four

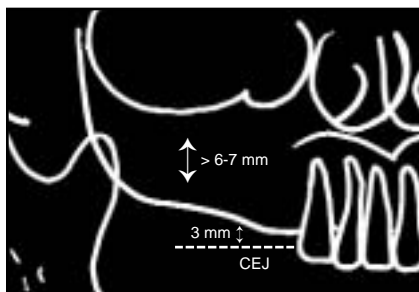


Fig 1a (left) Class A: Bone crest is about 3 mm from CEJ of adjacent teeth. Alveolar bone height is at least 6 to 7 mm.

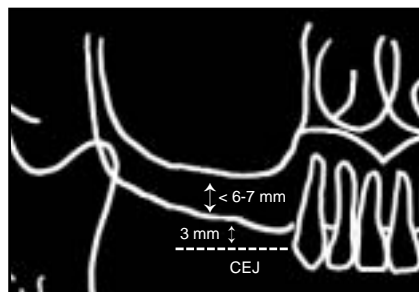


Fig 1b (right) Class B: Bone crest is about 3 mm from CEJ of adjacent teeth. Alveolar bone height is less than 6 to 7 mm (increased pneumatization of maxillary sinus).

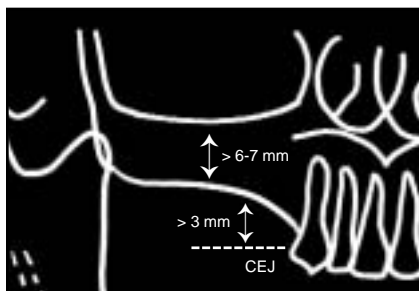


Fig 1c (left) Class C: Bone crest is more than 3 mm from CEJ of adjacent teeth. Alveolar bone height is at least 6 to 7 mm.

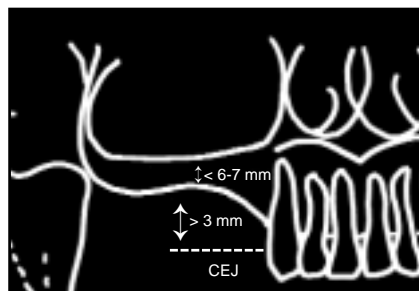


Fig 1d (right) Class D: Bone crest is more than 3 mm from CEJ of adjacent teeth. Alveolar bone height is less than 6 to 7 mm (increased pneumatization of maxillary sinus).

classes. Class I has a bilateral edentulous space, Class II has a unilateral edentulous space, Class III has an interdental edentulous area, and Class IV has an anterior edentulous area crossing the midline. This classification has been modified by Misch and Judy⁶; they divided each of the four Kennedy Classes into four divisions based on the height, length, and thickness of available bone.

In the present article, a classification of the maxillary posterior edentulous jaw is proposed to provide some guidelines for rehabilitation with osseointegrated implants and regenerative procedures (Fig 1):

- Class A: The bone crest is located about 3 mm from the cemento-enamel junction (CEJ) of the adjacent teeth. The alveolar bone height is at least 6 to 7 mm.

- Class B: The bone crest is located about 3 mm from the CEJ of the adjacent teeth. The alveolar bone height is less than 6 to 7 mm (increased pneumatization of the maxillary sinus).
- Class C: The bone crest is located more than 3 mm from the CEJ of the adjacent teeth. The alveolar bone height is at least 6 to 7 mm.
- Class D: The bone crest is located more than 3 mm from the CEJ of the adjacent teeth. The alveolar bone height is less than 6 to 7 mm (increased pneumatization of the maxillary sinus).

Class A patients are easily handled, since no regenerative procedures are required and implants can be placed following the standard protocol.¹

Class B patients present a large maxillary sinus but no resorption of the crestal bone, with a normal inter-arch distance. This situation can be overcome with the sinus floor elevation technique. In these patients, primary stabilization of the implants is often difficult due to the inadequate width and height of the available bone.⁷ Elevation of the Schneiderian membrane for the augmentation of the maxillary sinus was first described by Boyne and James.⁸ Tatum⁹ introduced the "one-step" procedure, which indicates the simultaneous placement of implants and the lateral wall procedure. Several clinical reports have attempted to evaluate the maxillary sinus elevation technique by using a variety of bone grafting materials, such as autogenous bone from the iliac crest^{8,10-12} or oral cavity,¹³⁻¹⁷ as well as bone substitutes, such as

freeze-dried bone allograft (FDBA),¹⁸ hydroxyapatite,¹⁸⁻²⁰ and xenograft.^{18,21} A 1996 conference attempting to reach consensus on the optimal treatment protocol concluded that, "The database was so multivariate and multifactorial that it was difficult to draw a definitive conclusion. . . ." ²² However, "several statements were obtained, the most significant being that the sinus graft should be considered a highly predictable and effective therapeutic method."²²

Class C patients show vertical resorption of the crestal bone and a consequent increase of the interarch distance. A vertical ridge augmentation technique with GBR is required to avoid an unfavorable implant-crown ratio that could lead to biomechanical and esthetic problems. The possibility of vertical ridge augmentation has been claimed by several authors using different procedures.²³⁻²⁵ Simion et al²⁶ showed the possibility of vertical ridge augmentation up to 4 mm using an expanded polytetrafluoroethylene (e-PTFE) membrane to protect the underlying blood clot. Tinti et al²⁷ combined the same membrane technique with autogenous bone graft harvested with a bone filter from the implant site preparation, obtaining a mean augmentation of 4.95 mm. Others²⁸ found a beneficial effect of the addition of demineralized FDBA (DFDBA) or autogenous bone particles to vertical ridge augmentation in humans. Furthermore, several authors demonstrate the long-term stability of osseointegrated implants placed at

the time of or after bone augmentation.²⁹⁻³²

In Class D patients, the atrophy is so severe that apical migration of the crestal bone is associated with a large maxillary sinus. This situation cannot be successfully managed with vertical ridge augmentation or a sinus elevation alone. The GBR procedure alone would lead to a correct interarch distance, but the bone height would not be sufficient to allow implant placement; sinus elevation alone would permit the placement of implants in an incorrect apicocoronal position. A review of the literature has shown no specific guidelines to handle this situation.

The aim of the present clinical study was to retrospectively evaluate 38 implants consecutively placed between October 1995 and January 2002 in 16 surgical sites, where severe atrophy of the posterior maxilla was treated by combining a sinus elevation with the vertical ridge regenerative procedure.

Method and materials

Fourteen partially edentulous patients treated in the Department of Periodontology and Implant Rehabilitation, University of Milan, School of Dentistry were selected for this study. The criteria chosen for including the patients were: (1) severe crestal atrophy and significant pneumatization of the maxillary sinus (Class D according to the classification proposed by the authors); and (2) the possibility of implant placement by combining a GBR technique for vertical ridge augmentation and sinus floor elevation.

Three patients were male, and 11 were female. Twelve patients showed Kennedy Class II edentulism, whereas two patients showed bilateral partial edentulism (Kennedy Class I). The age was between 48 and 63 years (mean 53 years). All patients were in good general health, without any detectable contraindication to implant surgery. Four of them were smokers (> 20 cigarettes a day). After a complete examination of oral conditions, all patients underwent professional oral hygiene. Periapical radiographs, orthopantomograms, and, in some cases, computerized tomography (CT) scan examination were used to assess the morphology of the alveolar ridges. A clear explanation about the nature and complications of the surgical technique to be performed was followed by a written consent form.

A total of 38 Brånemark implants (Nobel Biocare) of the submerged type with a machined surface and a length between 10 and

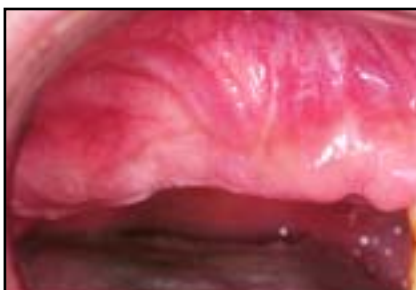

Fig 2a Atrophic edentulous ridge in posterior maxilla characterized by anatomic conditions required for participation in the study.

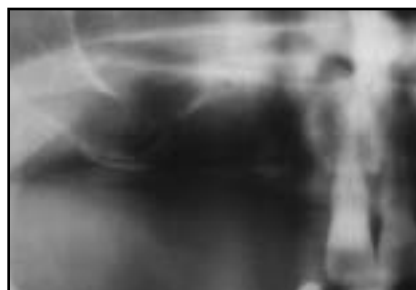

Fig 2b Orthopantomogram (patient VP) demonstrates vertical bone defect contiguous to maxillary sinus.

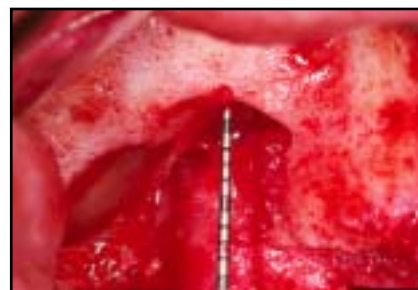

Fig 2c After full-thickness flap elevation, vertical bone is exposed. Defect height is about 13 mm.

15 mm were placed. Two different surgical techniques were adopted. In seven patients (16 implants), implants were placed at the same stage as the regenerative procedure (one-stage group), thanks to the availability of at least 6 mm of residual alveolar bone necessary to achieve primary implant stability. In the other seven patients (22 implants), implant placement was performed at second-stage surgery, after 6 to 13 months of submerged membrane healing (two-stage group). Titanium-reinforced e-PTFE membranes (WL Gore) were used for the regenerative procedures. Nine of the sixteen e-PTFE membranes used were of the TR9W type, and seven were TR6Y.

After the final prosthetic restoration, each patient underwent a maintenance program consisting of oral hygiene and clinical evaluation every 6 months and radiographic examination once a year. Each implant was classified as a success, survival, or failure according to the criteria of Albrektsson et al.³³ Moreover, the radiographic parameter of the

distance between the top of the implant shoulder and the first visible bone-implant contact (DIB)^{34,35} was assessed for every implant at the mesial and distal sides. DIB measurements were taken at abutment connection and every year at the radiographic examination.

Surgical procedure

The surgical procedures were performed in an operating room with strict hygienic conditions. Pre-surgical preparation of the patient included a chlorhexidine digluconate 0.2% mouthrinse (Corsodyl, GlaxoSmithKline) for 2 minutes and an extraoral scrub with a povidone-iodine solution (Betadine, Viatris) prior to draping. Local anesthesia with articaine 4% and epinephrine 1:100,000 (Citocartin 100, Molteni Dental) and a sedative premedication (diazepam, Valium-2, Roche) were administered before the surgery. Details about the surgical procedure have been described before³⁶; therefore, the most

important surgical steps are summarized (Figs 2 and 3).

Meticulous preparation of the recipient site is critical for the successful outcome of the regenerative technique. The surgical procedure was started with a crestal incision slightly buccal in keratinized mucosa. The incision was continued intrasulcularly at the two adjacent mesial teeth. Releasing incisions were made at the mesial and distal aspects of the flap, and a full-thickness flap was elevated. A continuous releasing periosteal incision was made connecting the mesial and distal releasing incisions on the initial flap to achieve, at the end of the surgery, a completely tension-free suture. After careful removal of the residual connective tissues on the top of the crestal bone, opening of the lateral wall of the maxillary bone was performed using high-speed instrumentation to create an oval window of about 8 mm × 10 mm in the anterolateral maxilla.³⁷ The membrane was dissected using properly designed sinus elevators (Hu-Friedy), and the bone window was reflected

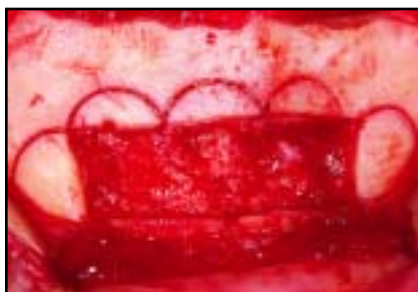

Fig 2d Two bone blocks and bone chips are harvested from mental symphysis.

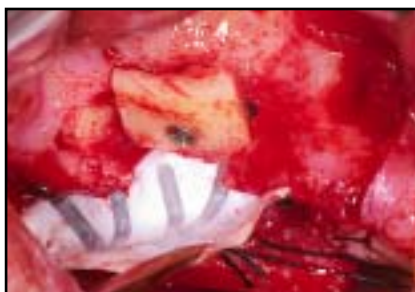

Fig 2e Bone blocks stabilized into floor of sinus and at base of defect. Titanium-reinforced membrane is folded and fixed toward palatal aspect of ridge.

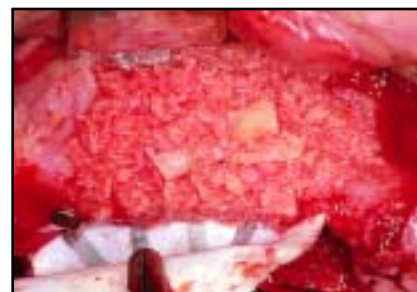


Fig 2f Autogenous bone chips mixed with Bio-Oss are packed into sinus and defect.

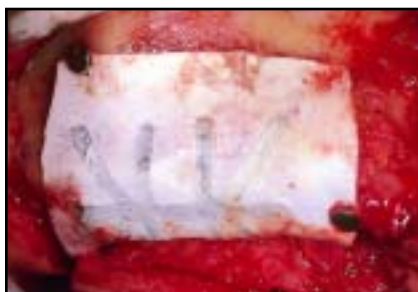

Fig 2g Titanium-reinforced membrane is positioned and stabilized with titanium tacks.

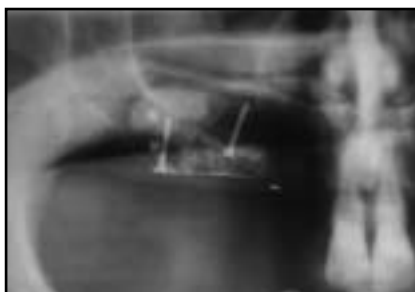

Fig 2h Orthopantomogram demonstrates bone graft and membrane in position.

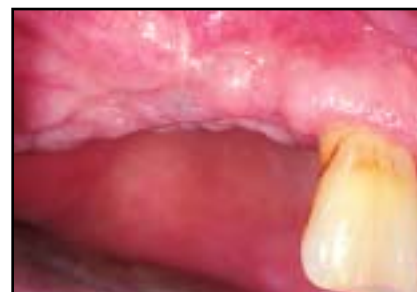

Fig 2i Augmented site just prior to membrane removal and implant placement after 6 months of uneventful healing.

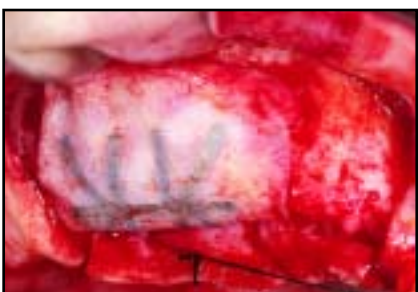

Fig 2j (left) At removal, membrane is in proper position, with no clinical sign of inflammation.

Fig 2k (right) After membrane removal, it is possible to recognize the regenerated bone.

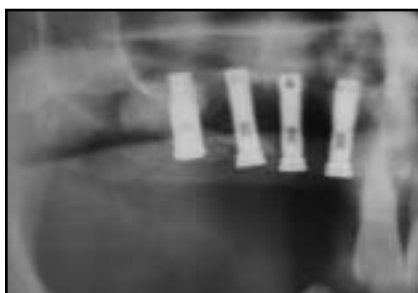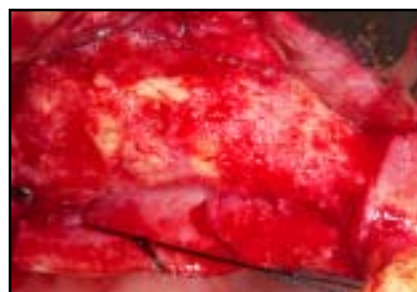


Fig 2l (left) Orthopantomogram shows implants in maxillary right lateral incisor to second premolar sites at time of membrane removal.

Fig 2m (right) Orthopantomogram after 5 years of prosthetic loading. Minor crestal bone remodeling is visible at canine site.

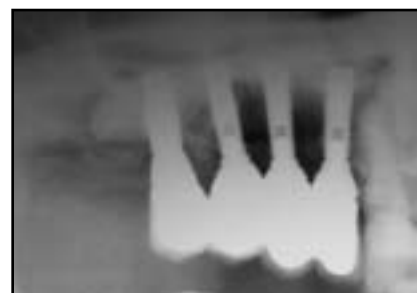

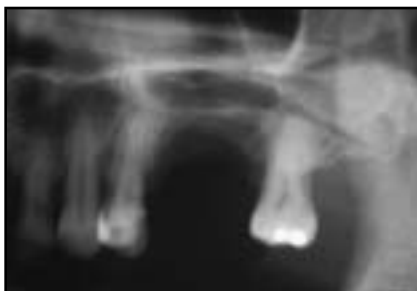


Fig 3a (left) Orthopantomogram (patient NL) shows atrophic edentulous ridge at maxillary left second premolar and first molar sites.

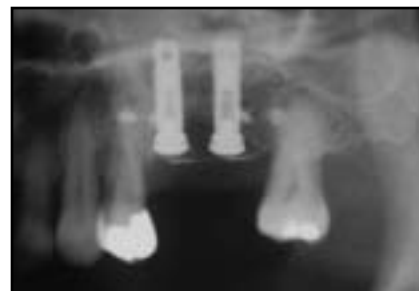

Fig 3b (right) Two Brånemark implants are placed in ideal prosthetic position at time of sinus elevation and vertical ridge augmentation.

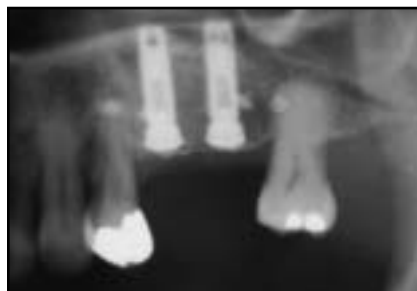

Fig 3c (left) Radiographic control after 13 months of healing, just before membrane removal.

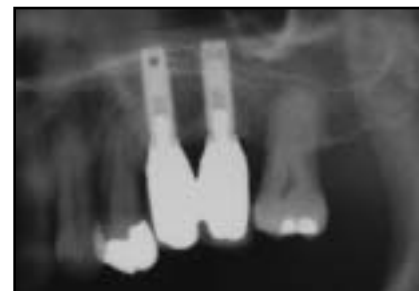

Fig 3d (right) Orthopantomogram after 7 years of prosthetic loading. Peri-implant regenerated bone at left second premolar and first molar sites and bone level of first premolar are radiographically stable.

as the roof of the cavity in which the graft had to be inserted. The graft was harvested from the mandibular symphysis in eight patients and from the ramus (retromolar region) in seven cases.

Ramus donor site

This donor site is usually chosen when the third molar is missing and when only a limited amount of bone is required. The incision started 2 to 3 mm distal from the second molar, with a distovestibular direction. A vertical releasing incision was made at the mesial aspect of the crestal incision. The flap was then elevated, and the bone was collected using trephine burs (8 and 10 mm in diameter) and chisels to remove the bone

blocks. Attention should be paid to leave at least 3 mm of intact bone above the alveolar nerve and not to touch the lingual wall of the ramus. The flap was closed with single interrupted sutures.

Mandibular symphysis donor site

A horizontal full-thickness incision was made from canine to canine about 10 mm apical to the mucogingival junction. After flap elevation, the bone was collected using trephine burs (8 mm diameter) and chisels. The depth of each cut should be related to the dimension of the donor site but is usually about 5 to 6 mm. The coronal limit of the area of bone harvesting is located about

5 mm apical of the apex of the anterior teeth; the apical limit is 5 mm coronal to the inferior border of the chin; and the lateral limit is 5 mm mesial to the mental foramen.³⁸ A collagen sponge (Gingostat, Vebas) was placed as a hemostatic agent in the donor site to reduce postoperative swelling and hematoma formation. The flap was closed with a two-layer suturing technique. The internal layer was sutured with a resorbable material and a horizontal mattress technique; the external layer was sutured with a nonresorbable material and a continuous technique.

The harvested bone was then particulated using a bone mill (R Quetin). Particulated bone was also collected with bone filters in the suction tips. Because of the anatomy of

the defect in two patients, the graft was positioned as a block. For the vertical ridge augmentation procedure, only autogenous graft was used; for the sinus floor elevation technique, the autogenous bone graft was mixed with anorganic bovine bone (Bio-Oss, Geistlich) in a 1:1 ratio in all patients except two (LE and OA; Table 1). The autogenous xenograft combination was used to add the osteoconductive properties of the xenograft to the osteogenetic and osteoinductive properties of the autogenous bone. Moreover, the necessity of major surgery to collect the bone was always avoided.

Positioning bone graft in recipient site

In the one-stage group, vertical ridge augmentation was started by positioning the implants protruding 2 to 7 mm from the top of the bone surface. In the two-stage group, ridge augmentation was started by positioning two tenting screws (Osteomed) on top of the residual ridge to maintain an adequate space underneath the membrane.

Several drill holes were performed on the cortical bone surface to ensure bleeding and activate bone formation. A TR6Y or a TR9W titanium-reinforced membrane was then carefully adapted to the crestal defect and fixed with mini-screws in the palatal portion of the area to be regenerated. The membrane was trimmed so that the margins overlapped the residual crestal bone by at least 3 to 4 mm.

Particular attention was paid to avoid any interference with the periodontal structures of the adjacent teeth.

The particulated graft was then placed underneath the partially fixed membrane and inside the sinus to completely fill the space. The membrane was then folded over and definitively fixated in the buccal portion of the maxillary bone using mini-screws to avoid any possible movements of the membrane or underlying grafted bone. The flap was sutured with vertical mattress sutures (Gore-Tex, WL Gore) alternated with simple interrupted stitches.

Postoperative care

All patients underwent antibiotic prophylactic treatment starting 1 day before surgery and then twice a day for 1 week (amoxicillin/clavulanic acid, Augmentin, GlaxoSmithKline). After surgery, patients received an antiinflammatory agent for about 1 week (ketoprofen, Orudis, Aventis Pharma). All patients were checked for exposures of the regenerative material 1 week after surgery. Sutures were removed after 2 weeks, and patients were recalled once a month for the following 6 months.

Membrane removal was performed with a crestal incision and mesial and distal releasing incisions. The full-thickness flap was then elevated, and the membrane was gently dissected from the bone. The residual thin soft tissue layer between the membrane and regenerated bone was completely

removed to allow assessment of the amount of new bone formation. In the two-stage group, the tenting screws were removed and two to three Brånemark implants were placed following the standard protocol.¹

In the one-stage group, abutment surgery was performed at the time of membrane removal; in the two-stage group, it occurred 6 months after implant positioning. Healing abutments were maintained for 4 to 6 weeks to obtain proper healing of the soft tissue. The implants were progressively loaded during the following 6 months.

After the final prosthetic restoration, 13 patients underwent a maintenance program. One patient did not respond to the recalls and was withdrawn from the study. The follow-up was between 1 and 7 years (mean 3.4 years).

Table 1 Overview of 16 surgical sites where severe atrophy of posterior maxilla was treated by combining sinus elevation with vertical ridge regeneration

Patient	Age (y)	Sex	Smoker	Surgery date	Maxillary ridge site	Group (stages)*	Graft	Membrane type	No. of implants	Membrane healing time (mo)
NML	54	F	Yes	10/31/95	Left	One	AC + Bio-Oss	TR6Y	2	13
LL	50	F	No	05/09/96	Left	Two	AC + Bio-Oss	TR9W	2	6
VP	48	M	Yes	11/25/97	Right	Two	AC + Bio-Oss	TR9W	2	7
LE	51	M	No	12/11/97	Left	Two	AC	TR9W	2	7
CF	59	F	Yes	02/23/98	Right	One	ARS + Bio-Oss	TR6Y	2	8
LR (a)	58	F	No	09/08/98	Right	Two	AC + Bio-Oss	TR6Y	2	7
LR (b)	63	F	No	01/22/02	Left	Two	AC + Bio-Oss	TR9W	2	5
OA	59	F	No	11/25/98	Right	Two	AC	TR6Y	3	7
ZC	43	F	No	11/11/99	Left	One	ARS + Bio-Oss	TR6Y	2	7
SP	57	F	No	05/15/00	Left	One	AC + Bio-Oss	TR6Y	2	8
TE [†]	51	M	No	06/15/00	Left	One	ARS + Bio-Oss	TR6Y	2	—
FML	52	F	Yes	02/26/01	Left	One	ARS + Bio-Oss	TR9W	3	7
LM	55	F	No	11/14/01	Left	One	ARS + Bio-Oss	TR9W	3	6
MA (a)	48	F	No	05/17/01	Right	Two	ARS + Bio-Oss	TR9W	3	6
MA (b)	48	F	No	05/17/01	Left	Two	ARS + Bio-Oss	TR9W	3	6
SM [†]	57	F	No	06/23/98	Left	Two	AC + Bio-Oss	TR9W	3	1

*One stage = implants placed at time of regenerative procedures; two stages = implants placed at time of membrane removal.

[†]Membrane exposed; healing was uneventful in all other patients.

AC = autogenous from chin; ARS = autogenous from retromolar space.

Results

The clinical results of the study are summarized in Tables 1 and 2. Two membranes became exposed during the healing process (12.5%). One membrane exposure happened after 1 week; the membrane and one of the two implants were removed, and no regeneration was achieved. In the second case, the membrane became exposed after 5 weeks. The membrane was gently removed to avoid damage to the immature underlying tissue, and the implants were not removed because they were clinically stable. In the remaining 14 sites (87.5%), the membrane

remained covered for a 6- to 13-month healing period. At removal, no signs of inflammation of the surrounding tissues were noted, and the membrane was firmly attached to the underlying newly formed tissue. Membrane removal showed a thin soft tissue layer (less than 1 mm) covering a hard tissue with the clinical appearance of bone. The sinus augmentations were uneventful in all cases, without any sinusitis or loss of bone graft.

Sixteen implants (seven patients) were placed at time of the regenerative procedure; 22 implants (seven patients) were placed at the time of membrane

removal. The survival rate of the implants was 92.1%, whereas the success rate was 76.3% during the follow-up period from 1 to 7 years postloading. Three implants (7.9%) failed. All three failed implants were associated with the two surgical sites where membrane exposure happened. Implant 23 was removed just 1 week after the surgery because of membrane exposure, and no primary stabilization of the implant was achieved. Implants 36 and 37 were removed at second-stage surgery because no osseointegration was obtained. In all other cases, good primary stability was achieved and healing was successful.

Table 2 Overview of 38 Brånemark implants placed in 16 augmented sites

Patient	Implant No.	Site*	Implant type	Implant length (mm)	Implant diameter	Abutment connection date	Healing [†]	DIB0 mesial	DIB0 distal	DIB1 mesial	DIB1 distal	Follow-up (y)
NML	1	25	Mk II	13.0	RP	11/12/96	Success	0.0	0.0	1.0	1.0	7
	2	26	Mk II	13.0	RP		Success	0.0	0.0	1.5	1.5	
LL	3	25	Mk II	11.5	RP	09/09/97	Survival	0.0	0.0	5.0	6.0	6
	4	26	Mk II	11.5	RP		Survival	0.0	0.0	4.5	3.5	
VP	5	14	Mk II	15.0	RP	11/11/98	Success	0.0	0.0	1.0	1.5	5
	6	15	Mk II	13.0	WP		Success	0.0	0.0	1.5	2.0	
LE	7	24	Mk IV	13.0	RP	02/25/99	Success	-1.5	-1.0	1.0	1.0	4
	8	25	Mk IV	13.0	RP		Success	-1.0	-0.5	1.5	1.0	
CF	9	15	Mk II	15.0	RP	10/19/98	Survival	0.0	0.0	1.5	5.0	5
	10	16	Mk II	13.0	RP		Success	0.0	0.0	1.0	1.0	
LR	11	15	Mk IV	13.0	NP	10/04/99	Success	0.0	0.0	1.0	1.0	4
	12	16	Mk IV	13.0	RP		Success	0.0	0.0	1.5	1.5	
	13	25	Mk IV	13.0	RP	10/10/02	Success	0.0	0.0	1.0	1.0	
	14	26	Mk IV	13.0	RP		Success	0.0	0.0	1.0	1.0	
OA	15	14	Mk II	13.0	RP	11/25/99	Survival	0.0	1.5	1.5	5.0	4
	16	15	Mk II	10.0	RP		Survival	-1.0	1.0	2.0	3.0	
	17	16	Mk II	10.0	RP		Success	-1.0	1.0	1.5	1.5	
ZC	18	25	Mk IV	13.0	RP	05/18/00	Success	-2.0	0.0	—	—	WD
	19	26	Mk IV	13.0	RP		Success	-1.0	0.0	—	—	
SP	20	25	Mk IV	13.0	RP	01/11/01	Success	0.0	0.0	1.0	1.5	2
	21	26	Mk IV	13.0	RP		Success	0.0	0.0	1.5	1.0	
TE	22	25	Mk III	13.0	RP	06/20/00	Success	0.0	0.0	1.0	1.5	2
	23	27	Mk III	13.0	WP		Failure	—	—	—	—	
FML	24	24	Mk IV	13.0	RP	09/27/01	Success	0.0	0.0	1.0	1.5	2
	25	25	Mk IV	13.0	RP		Success	0.0	0.0	1.0	1.0	
	26	26	Mk III	15.0	RP		Success	0.0	0.0	1.0	1.0	
LM	27	24	Mk III	13.0	RP	05/21/02	Success	0.0	0.0	1.0	1.0	1
	28	25	Mk III	13.0	RP		Success	0.0	0.0	1.0	1.0	
	29	26	Mk IV	13.0	RP		Success	0.0	0.0	1.0	1.0	
MA	30	14	Mk III	13.0	RP	06/06/02	Success	0.0	0.0	1.5	2.0	1
	31	15	Mk III	10.0	RP		Success	0.0	0.0	1.5	1.5	
	32	16	Mk IV	10.0	RP		Success	0.0	0.0	1.0	1.0	
	33	24	Mk IV	13.0	RP		Success	0.0	0.0	1.5	1.0	
	34	25	Mk III	13.0	RP		Success	0.0	0.0	2.0	1.5	
	35	26	Mk IV	10.0	RP		Success	0.0	0.0	1.5	1.5	
SM	36	24	Mk IV	13.0	RP	12/16/99	Failure	0.0	0.0	—	—	4
	37	25	Mk IV	13.0	RP		Failure	0.0	0.0	—	—	
	38	26	Mk IV	13.0	RP		Survival	0.0	0.0	2.5	1.0	

*Fédération Dentaire Internationale tooth-numbering system.

[†]According to criteria of Albrektsson et al.³³

DIB0 and DIB1 = distance between top of implant shoulder and first visible bone-implant contact at abutment connection and last follow-up, respectively; RP = Regular Platform; WP = Wide Platform; NP = Narrow Platform; WD = withdrawal.

At abutment connection, the mean DIB was -0.14 mm (range -2.0 to 0.0 mm, standard deviation [SD] 0.38) at the mesial side and 0.06 mm (range -1.0 to 1.5 mm, SD 0.41) at the distal side; at the last follow-up, the mean DIB was 1.52 mm (range 1.0 to 5.0 mm, SD 0.91) at the mesial side and 1.74 mm (range 1.0 to 6.0 mm, SD 1.29) at the distal side. A comparison of the DIB values between abutment connection (DIB 0) and the last examination (DIB 1) showed a mean crestal loss (Δ DIB) of 1.65 mm (SD 0.98) at the mesial side and 1.68 mm (SD 1.18) at the distal side.

Discussion

This retrospective clinical study provides the first 1- to 7-year results on implants placed combining the techniques of sinus floor elevation and vertical ridge augmentation in the same surgical site. Almost all data were in accordance with a previous long-term study³¹ on osseointegrated implants placed in vertically augmented bone with a membrane technique. That study retrospectively considered 123 implants consecutively placed in 53 vertically augmented ridges and evaluated after a period of functional loading varying from 16 to 69 months. Radiographic analysis showed stable bone crest levels, with a mean bone loss varying from 1.35 to 1.87 mm during the period of observation. On the basis of the presented results, the authors concluded that bone vertically augmented with GBR techniques

responds to implant placement like native, nonregenerated bone.

In the present study, three of 38 implants failed, for a survival rate of 92.1% and a success rate of 76.3%. The implant failure was clearly a consequence of the lack of bone regeneration associated with the early membrane exposure and removal.

At the first-year examination, six implants (Nos. 3, 4, 9, 15, 16, and 38) demonstrated crestal bone loss (Δ DIB) greater than the normal value of 1.5 to 2.0 mm. However, bacterial infection can be excluded as an etiologic factor because of the absence of clinical signs of marginal inflammation or purulent exudate. Since the bone level remained stable at the following examinations, the bone loss could be ascribed more to excessive remodeling of the immature regenerated bone after prosthetic loading. All remaining implants appeared clinically stable, and no signs of radiolucency were present at the bone-implant interface; therefore, these could be defined as successfully osseointegrated according to the criteria of Albrektsson et al.³³

In the present study, the success rate of the implants (76.3%) was not in accordance with a previous long-term study,³¹ where the success rate of implants positioned with vertical ridge augmentation was 97.5%. According to the authors, this difference is because, in the present study, implants were placed only in the maxillary posterior jaw (the bone quality is lower than in the mandible) and because of the association with the sinus elevation technique.

The results of the present retrospective study provide the first human data on implants placed in jawbone vertically augmented with GBR techniques associated with sinus floor elevation following 1 to 7 years of functional load. The mean bone loss of 1.65 to 1.68 mm is also in accordance with previous long-term studies on implants placed in horizontally regenerated bone.^{29,39-44}

The bone regenerated vertically by means of sinus floor elevation and supracrestal GBR showed the same biologic behavior as native, nonregenerated bone; however, in a few cases, its remodeling pattern seemed to determine slightly higher bone crest resorption. This possible phenomenon must be taken into account during surgical treatment planning; overcorrection of the vertical bone level could be necessary. Further research is also needed to evaluate the possibility of reducing bone crest resorption by using anorganic bovine bone for vertical ridge augmentation, as suggested by Zitzmann et al.⁴⁵

References

1. Adell R, Lekholm U, Rockler B, Brånemark P-I. A 15-year study of osseointegrated implants in the treatment of the edentulous jaw. *Int J Oral Surg* 1981;10:387-416.
2. Nevins M, Langer B. The successful application of osseointegrated implants to the posterior jaw: A long-term retrospective study. *Int J Oral Maxillofac Implants* 1993;8:428-432.
3. Cummer WE. Possible combinations of teeth present and missing in partial restorations. *Oral Health* 1920;10:421-426.
4. Kennedy E. Partial denture construction. In: *Dental Items of Interest*, 1928.
5. Cawood JI, Howell RA. A classification of the edentulous jaws. *Int J Oral Maxillofac Surg* 1988;17:232-236.
6. Misch CE, Judy WMK. Classifications of the partially edentulous arches for implant dentistry. *Int J Oral Implantol* 1987;4:7-12.
7. Jemt T, Lekholm U. Implant treatment in edentulous maxillae: A 5-year follow-up report on patients with different degrees of jaw resorption. *Int J Oral Maxillofac Implants* 1995;10:303-311.
8. Boyne PJ, James RA. Grafting of the maxillary sinus floor with autogenous marrow and bone. *J Oral Surg* 1980;38:613-616.
9. Tatum H. Maxillary and sinus implant reconstructions. *Dent Clin North Am* 1986;30:207-229.
10. Kent JN, Block MS. Simultaneous maxillary sinus floor bone grafting and placement of HA-coated implants. *J Oral Maxillofac Surg* 1989;47:238-242.
11. Jensen OT, Simonsen EK, Sindet-Pedersen S. Reconstruction of the severely resorbed maxilla with bone grafting and osseointegrated implants: A preliminary report. *J Oral Maxillofac Surg* 1990;48:27-32.
12. Misch CE, Dietsch F. Endosteal implants and iliac crest grafts to restore severely resorbed totally edentulous maxillae—A retrospective study. *J Oral Implantol* 1994;20:100-110.

13. Lundgren S, Moy P, Johansson C, Nilsson H. Augmentation of the maxillary sinus floor with particulated mandible: A histologic and histomorphometric study. *Int J Oral Maxillofac Implants* 1996;11:760-766.
14. Hirsch JM, Ericsson I. Maxillary sinus augmentation using mandibular bone grafts and simultaneous installation of implants. A surgical technique. *Clin Oral Implants Res* 1991;2:91-96.
15. Jensen J, Sindet-Pedersen S. Autogenous mandibular bone grafts and osseointegrated implants for reconstruction of the severely atrophied maxilla: A preliminary report. *J Oral Maxillofac Surg* 1991;49:1277-1287.
16. Khoury F. Augmentation of the sinus floor with mandibular bone block and simultaneous implantation: A 6-year clinical investigation. *Int J Oral Maxillofac Implants* 1999;14:557-564.
17. Wood RM, Moore DL. Grafting of the maxillary sinus with intraorally harvested autogenous bone prior to implant placement. *Int J Oral Maxillofac Implants* 1988;3:209-214.
18. Smiler DG, Johnson PW, Lozada JL, et al. Sinus lift grafts and endosseous implants. Treatment of the atrophic posterior maxilla. *Dent Clin North Am* 1992;36:151-186.
19. Haas R, Mailath G, Dortbudak O, Watzek G. Bovine hydroxyapatite for maxillary sinus augmentation: Analysis of interfacial bond strength of dental implants using pull-out tests. *Clin Oral Implants Res* 1998;9:117-122.
20. Wagner JR. A 3 1/2-year clinical evaluation of resorbable hydroxylapatite OsteoGen (HA Resorb) used for sinus lift augmentations in conjunction with the insertion of endosseous implants. *J Oral Implantol* 1991;17:152-164.
21. Hürzeler MB, Kirsch A, Ackermann KL, Quiñones CR. Reconstruction of the severely resorbed maxilla with dental implants in the augmented maxillary sinus: A 5-year clinical investigation. *Int J Oral Maxillofac Implants* 1996;11:466-475.
22. Jensen OT, Shulman LB, Block MS, Iacono VJ. Report of the Sinus Consensus Conference of 1996. *Int J Oral Maxillofac Implants* 1998;13(suppl):11-45.
23. Parma Benfenati S, Tinti C, Albrektsson T, Johansson C. Histologic evaluation of guided vertical ridge augmentation around implants in humans. *Int J Periodontics Restorative Dent* 1999;19:424-437.
24. Tinti C. Vertical ridge augmentation: Surgical protocol and retrospective evaluation of 48 consecutively inserted implants. *Int J Periodontics Restorative Dent* 1998;18:434-443.
25. Simion M, Trisi P, Piattelli A. GBR with an e-PTFE membrane associated with DFDBA: Histologic and histochemical analysis in a human implant retrieved after 4 years of loading. *Int J Periodontics Restorative Dent* 1996;16:338-347.
26. Simion M, Trisi P, Piattelli A. Vertical ridge augmentation using a membrane technique associated with osseointegrated implants. *Int J Periodontics Restorative Dent* 1994;14:497-511.
27. Tinti C, Parma-Benfenati S, Polizzi G. Vertical ridge augmentation: What is the limit? *Int J Periodontics Restorative Dent* 1996;16:221-229.
28. Simion M, Jovanovic S, Trisi P, Scarano A, Piattelli A. Vertical ridge augmentation around dental implants using a membrane technique and autogenous bone or allograft in humans. *Int J Periodontics Restorative Dent* 1998;18:9-23.
29. Nevins M, Mellonig JT, Clem DS III, Reiser GM, Buser DA. Implants in regenerated bone: Long-term survival. *Int J Periodontics Restorative Dent* 1998;18:34-45.
30. Buser D, Dula K, Lang NP, Nyman S. Long term stability of osseointegrated implants in bone regenerated with the membrane technique: 5-year results of the first 12 implants. *Clin Oral Implants Res* 1996;7:175-183.

31. Simion M, Jovanovic SA, Tinti C, Parma Benfenati S. Long-term evaluation of osseointegrated implants inserted at the time of or after vertical ridge augmentation. A retrospective study on 123 implants with 1–5 year follow-up. *Clin Oral Implants Res* 2001;12:35–45.
32. Buser D, Ingimarsson S, Dula K, Lussi A, Hirt HP, Belser UC. Long-term stability of osseointegrated implants in augmented bone: A 5-year prospective study in partially edentulous patients. *Int J Periodontics Restorative Dent* 2002;22:108–117.
33. Albrektsson T, Zarb G, Worthington P, Eriksson B. Long-term efficacy of currently used dental implants: A review and proposed criteria of implant success. *Int J Oral Maxillofac Implants* 1986;1:11–25.
34. Buser D, Weber HP, Brägger U, Balsiger C. Tissue integration of one-stage ITI implants. 3-year results of a longitudinal study with hollow-cylinder and hollow-screw implants. *Int J Oral Maxillofac Implants* 1991;6:405–412.
35. Weber H, Buser D, Fiorellini J, Williams R. Radiographic evaluation of crestal bone levels adjacent to nonsubmerged titanium implants. *Clin Oral Implants Res* 1992;3:181–188.
36. Simion M. Procedures used to augment the deficient alveolar ridge. In: Lindhe J, Karring T, Lang NP (eds). *Clinical Periodontology and Implant Dentistry*, ed 4. Oxford, UK: Blackwell Munksgaard, 2003:897–914.
37. Small SA, Zinner ID, Panno FV, Shapiro HJ, Stein JI. Augmenting the maxillary sinus for implants: Report of 27 patients. *Int J Oral Maxillofac Implants* 1993;8:523–528.
38. Hunt DR, Jovanovic SA. Autogenous bone harvesting: A chin graft technique for particulate and monocortical bone blocks. *Int J Periodontics Restorative Dent* 1999;19:165–173.
39. Dahlin C, Lekholm U, Lindé A. Membrane-induced bone augmentation at titanium implants. A report on ten fixtures followed from 1 to 3 years after loading. *Int J Periodontics Restorative Dent* 1991;11:273–281.
40. Jovanovic SA, Spiekermann H, Richter EJ. Bone regeneration around titanium dental implants in dehiscence defect sites: A clinical study. *Int J Oral Maxillofac Implants* 1992;7:233–245.
41. Dahlin C, Lekholm U, Becker W, et al. Treatment of fenestration and dehiscence bone defects around oral implants using the guided tissue regeneration technique: A prospective multicenter study. *Int J Oral Maxillofac Implants* 1995;10:312–318.
42. Fugazzotto PA. Success and failure rates of osseointegrated implants in function in regenerated bone for 6 to 51 months: A preliminary report. *Int J Oral Maxillofac Implants* 1997;12:17–24.
43. von Arx T, Wallkamm B, Hardt N. Localized ridge augmentation using a micro titanium mesh: A report on 27 implants followed from 1 to 3 years after functional loading. *Clin Oral Implants Res* 1998;9:123–130.
44. Palmer RM, Smith BJ, Palmer PJ, Floyd PD, Johansson CB, Albrektsson T. Effect of loading on bone regenerated at implant dehiscence sites in humans. *Clin Oral Implants Res* 1998;9:283–291.
45. Zitzmann NU, Schärer P, Marinello CP, Schupbach P, Berglundh T. Alveolar ridge augmentation with Bio-Oss: A histologic study in humans. *Int J Periodontics Restorative Dent* 2001;21:288–295.