




Taiwan Academy of Osseointegration TAOi
Taipei 22-23 July 2017

PROSTHETIC HANDLING OF COMPROMISED SITES AND EXTENDED EDENTULOUS SPACES IN THE ANTERIOR MAXILLA

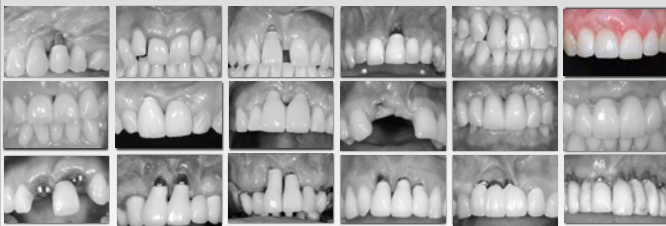
Urs | Belser

TOPICS



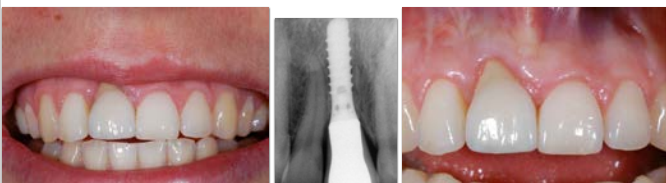- Introduction and Scope
- Implant prosthodontics in extended anterior edentulous spaces
- Guidelines for the use of "pink ceramics"
- Conclusions and perspectives 

Esthetic implant complications

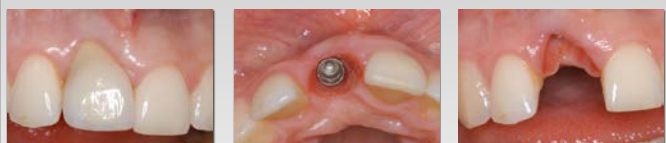

Treatment planning - case presentation

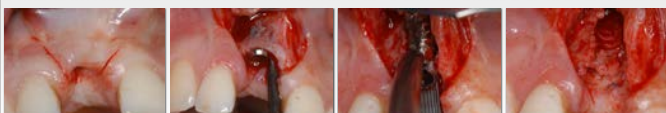
Esthetic implant complication



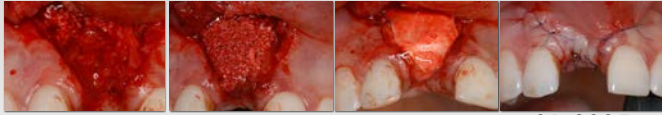
12-2004



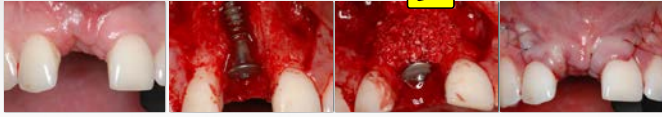
12-2004



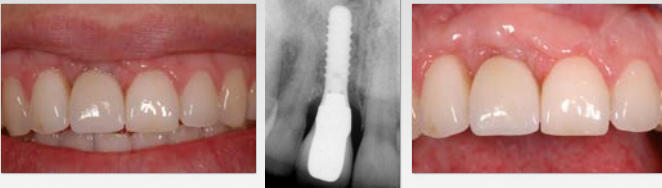
01-2005



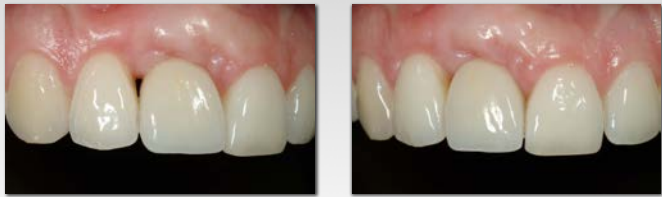01-2005



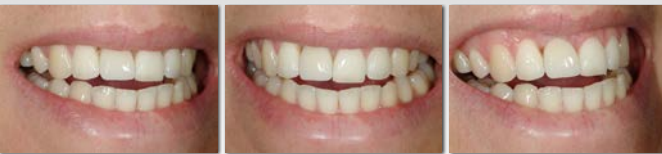05-2005




05-2006



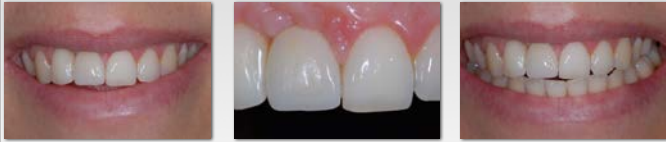2010: 4-year follow-up



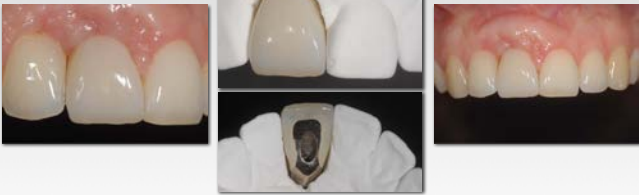2010: 4-year follow-up



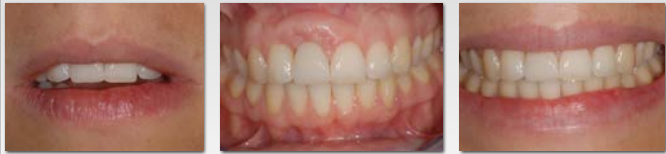2010: 4-year follow-up



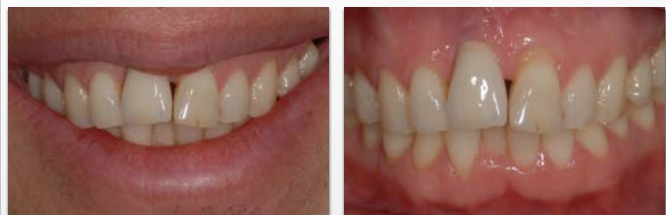2014: 8-year follow-up



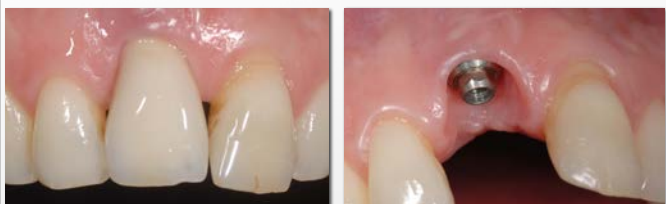2014: 8-year follow-up



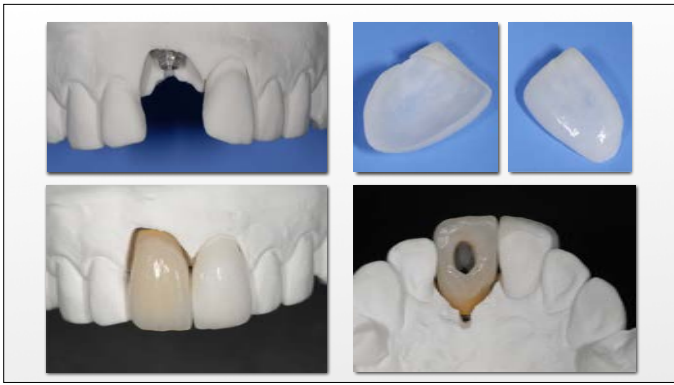2014: 8-year follow-up

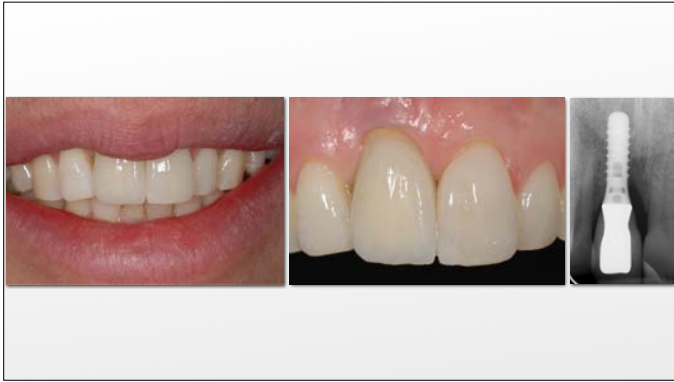


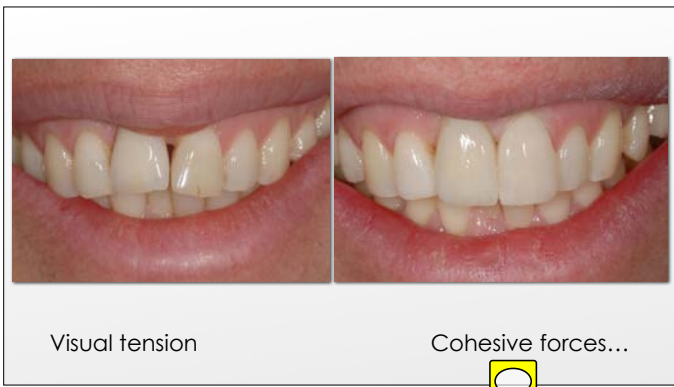15-yr follow-up



15-yr follow-up

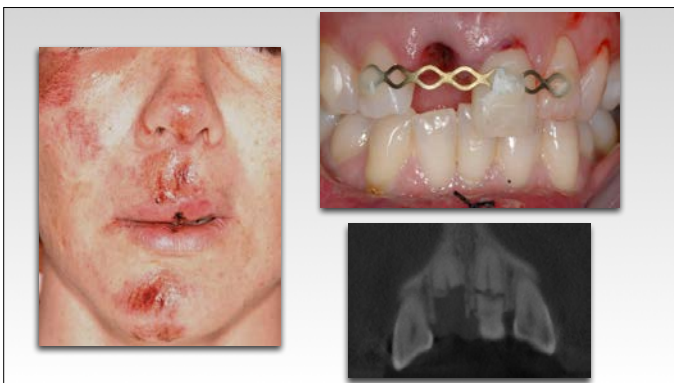


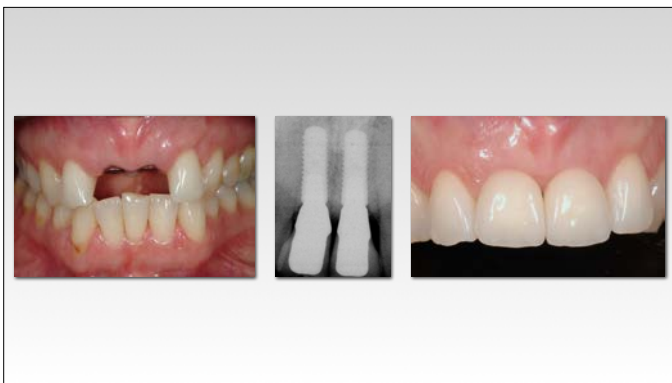
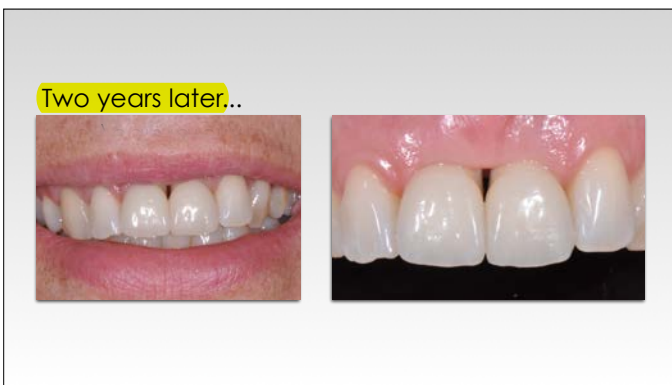


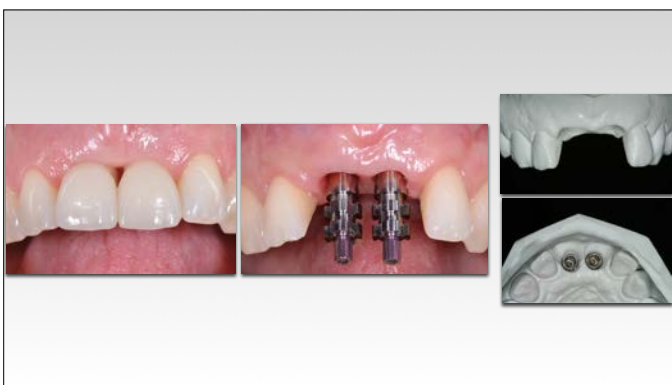Esthetic implant complications

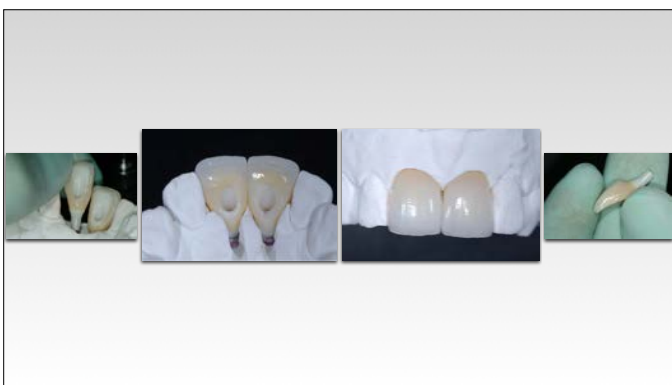
Treatment planning - case presentation

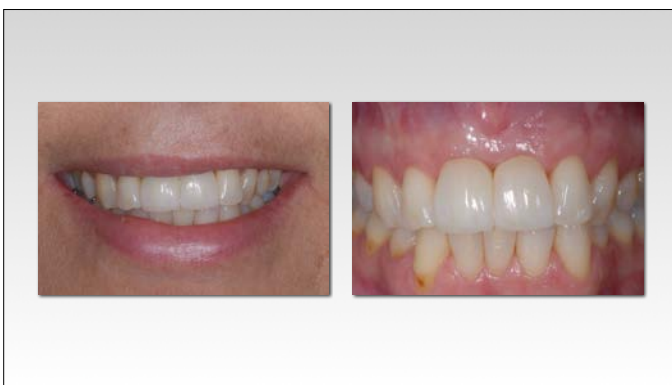


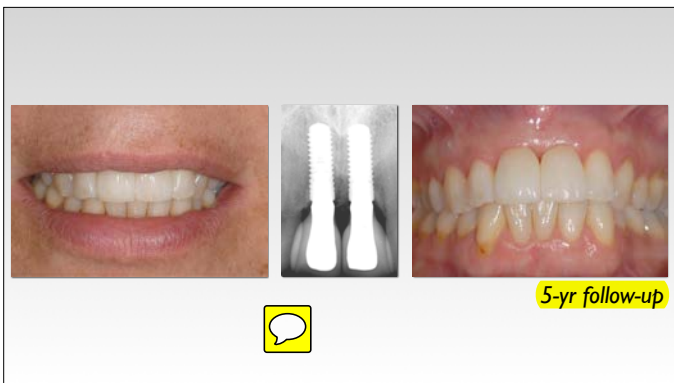


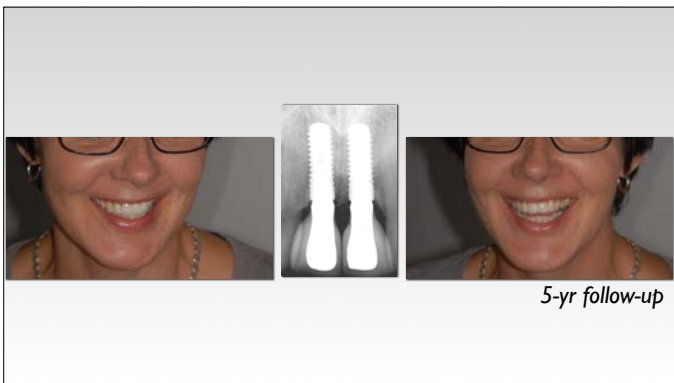


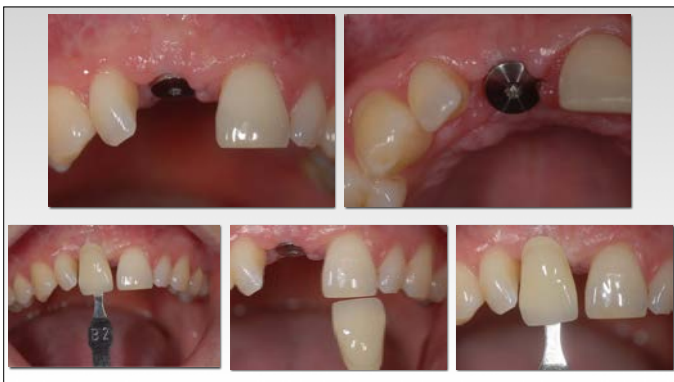


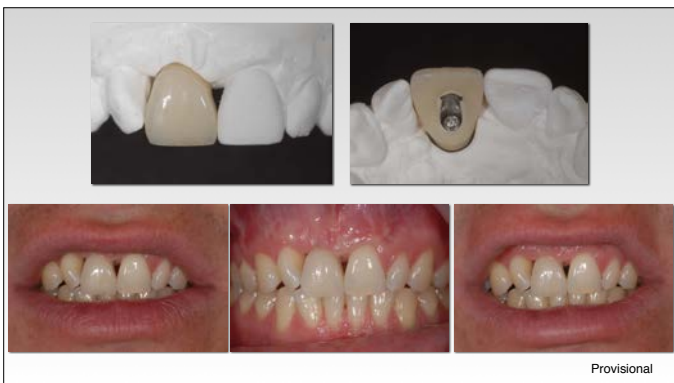


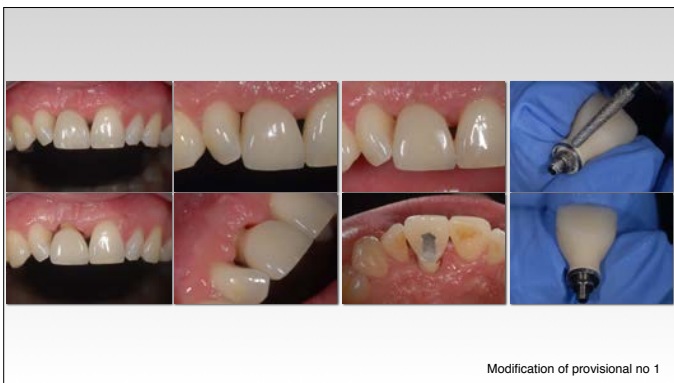


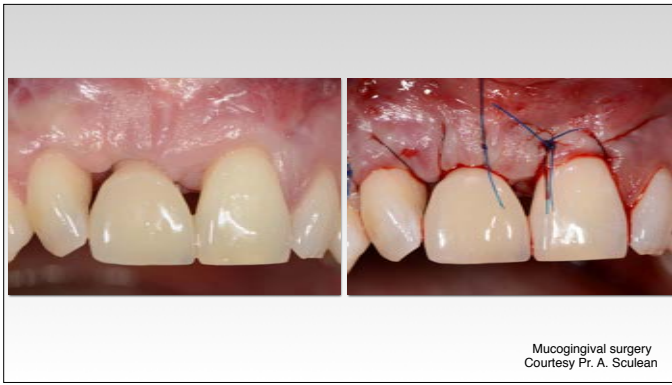




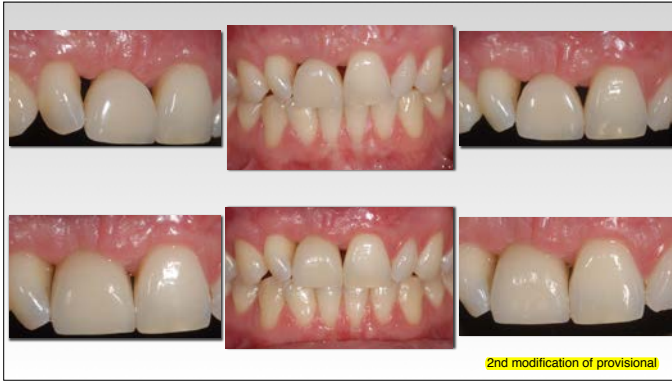



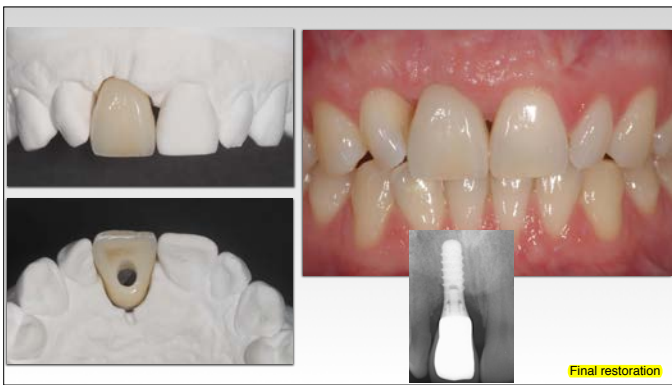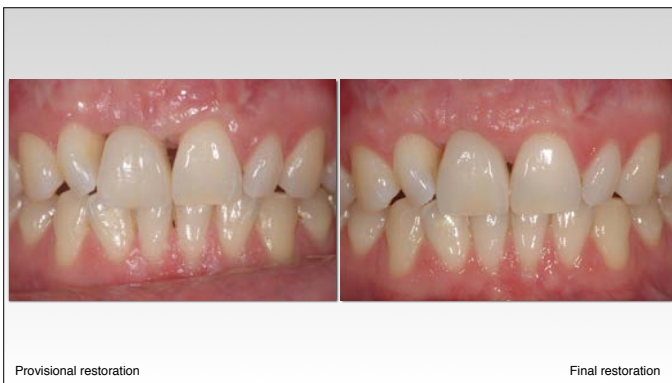
Mucogingival surgery
Courtesy Pr. A. Sculean



2nd modification of provisional

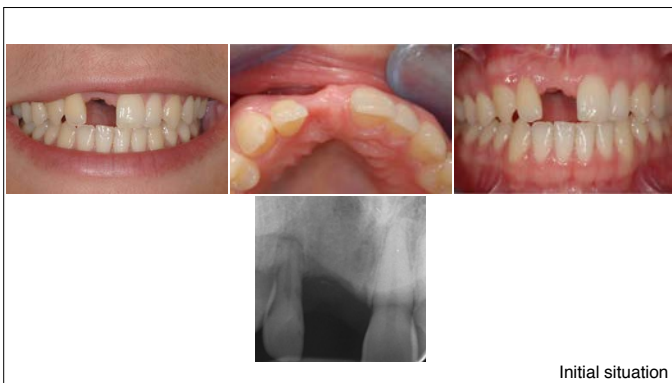


Final restoration

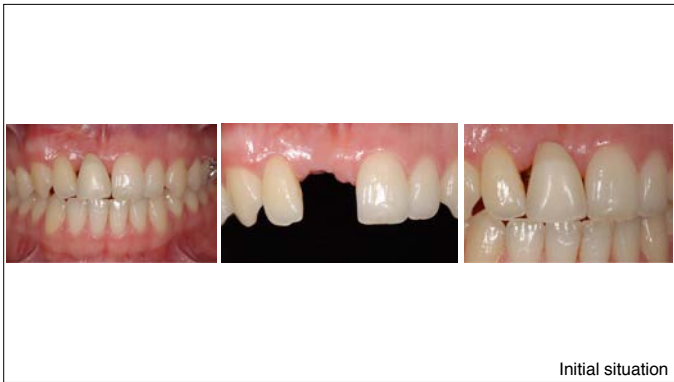

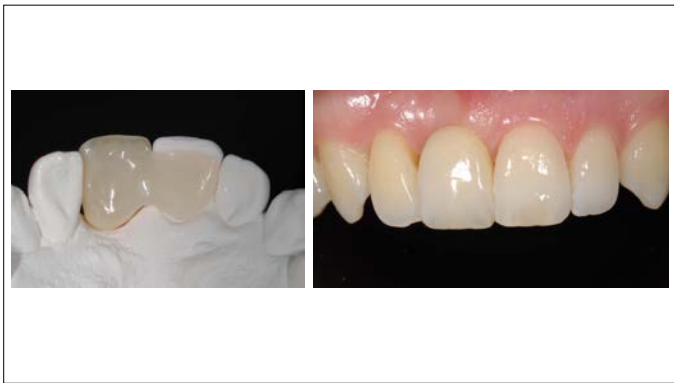
Provisional restoration

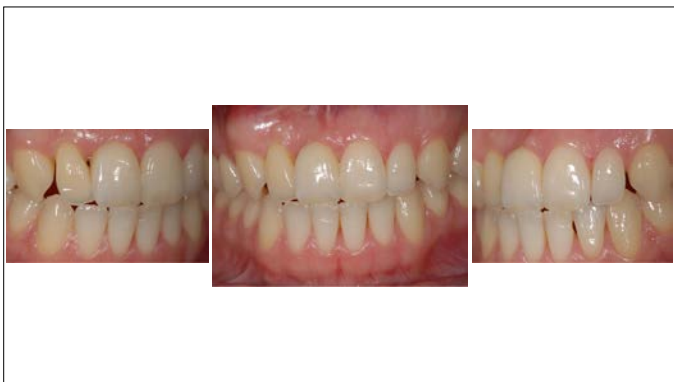Final restoration

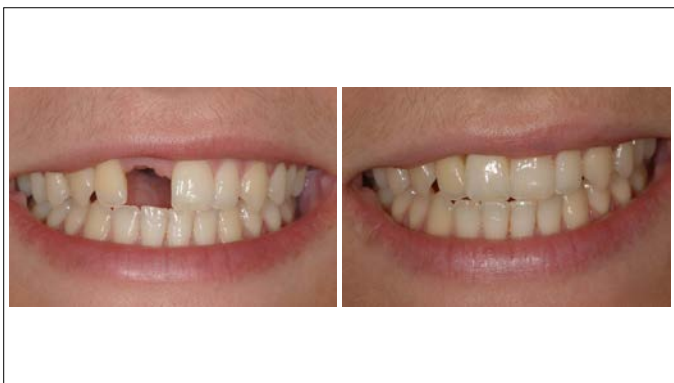


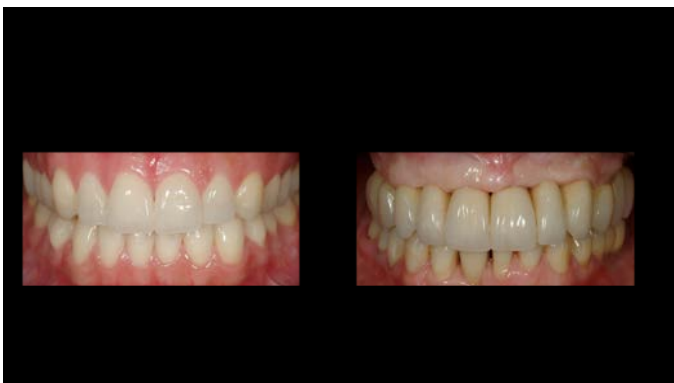Initial situation

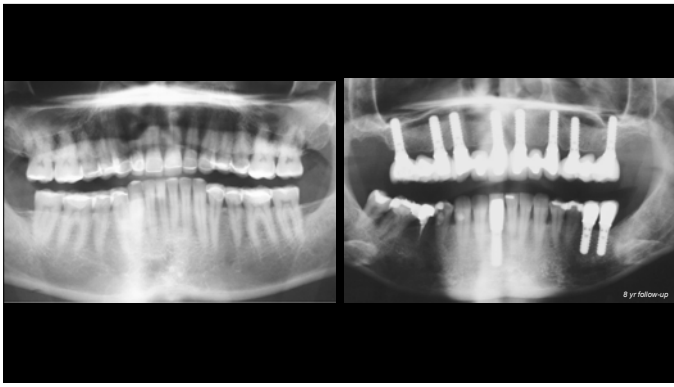


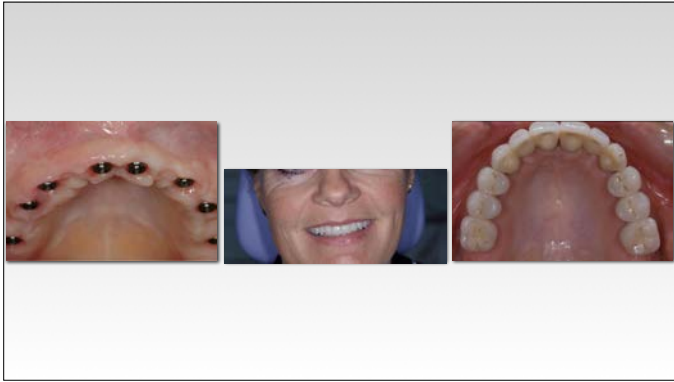


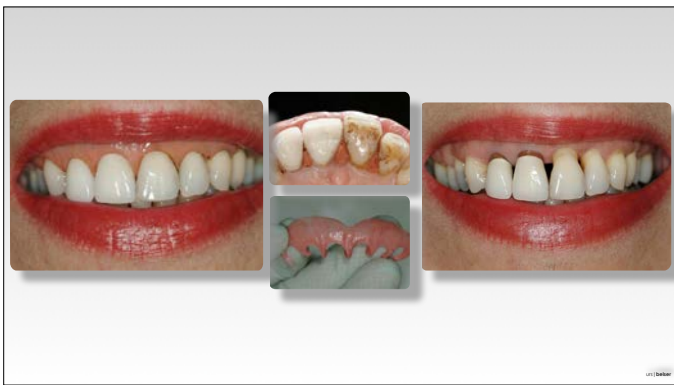

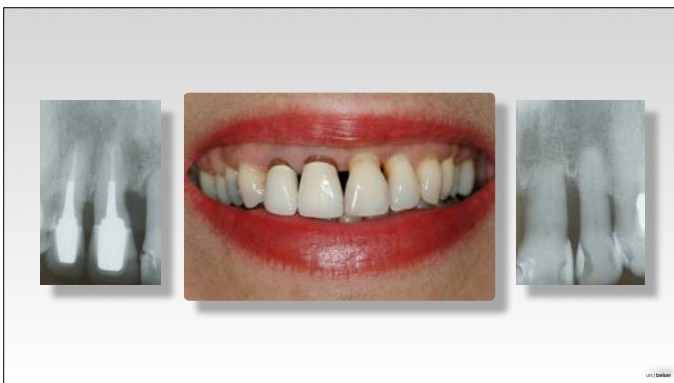














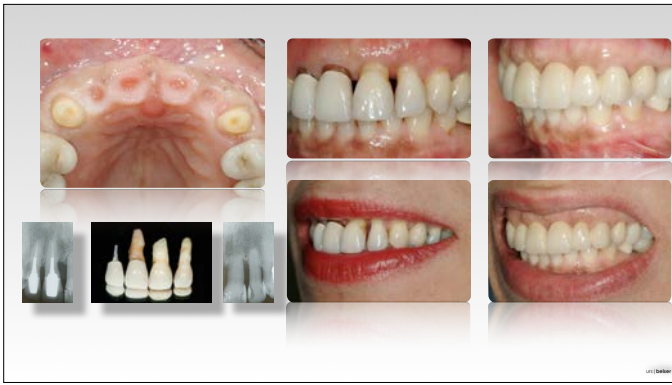
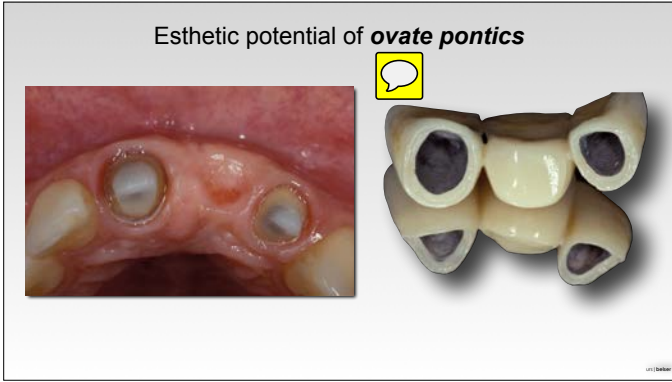
 **QUESTION** 

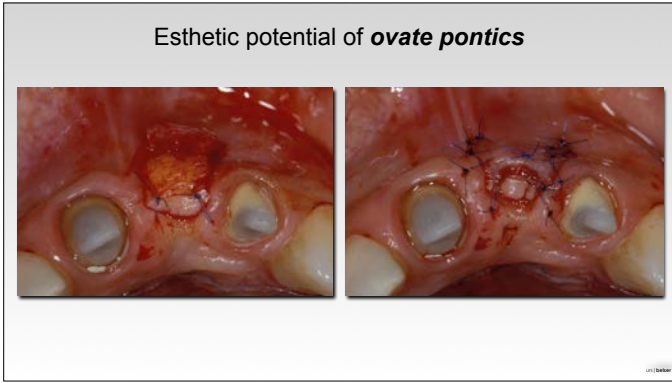
What treatment plan do you recommend?

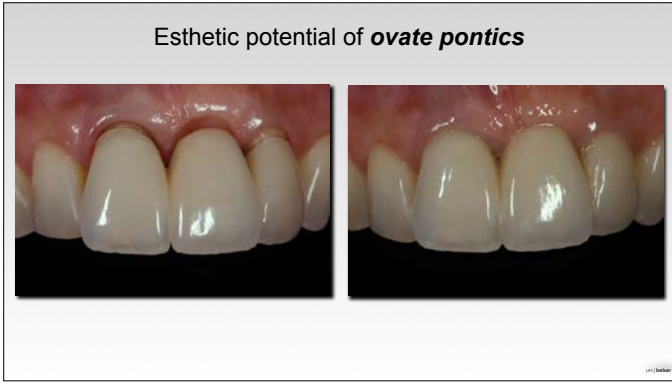- 1: Two new crowns I2/I1 and two veneers 21/22
- 2: Four all-ceramic crowns
- 3: Extraction of the 4 incisors and TLI I2/22
- 4: Extraction of the 4 incisors and BLI I2/22
- 5: Other







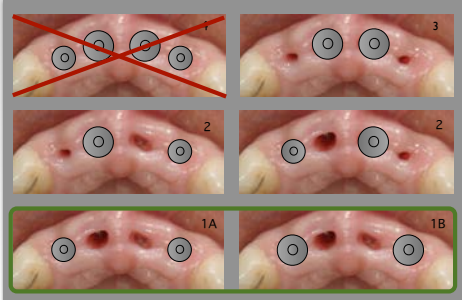




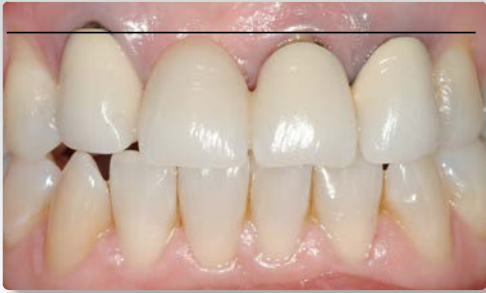TOPICS

- Introduction and Scope
- **Implant prosthodontics in extended anterior edentulous spaces**
- Guidelines for the use of "pink ceramics"
- Conclusions and perspectives

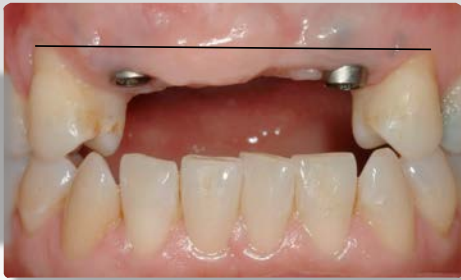Four missing maxillary incisors: implant treatment options



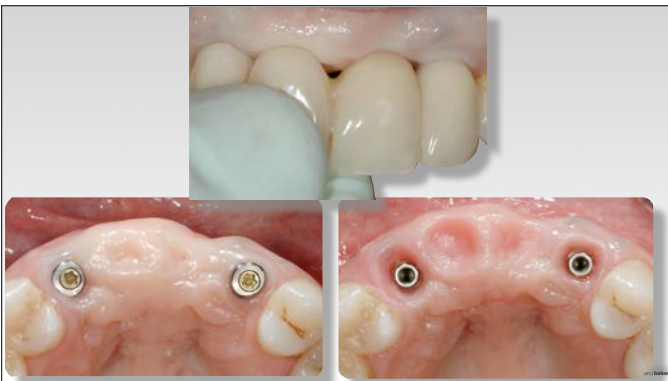Vallati F & Belsler UC. Eur J Esthet Dent 2:42-57, 2007



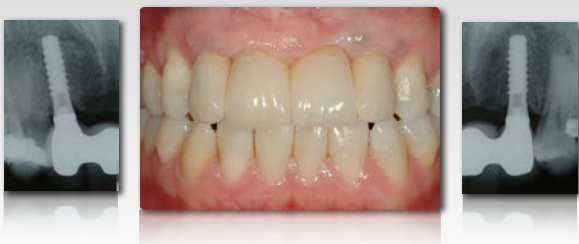© Belsler



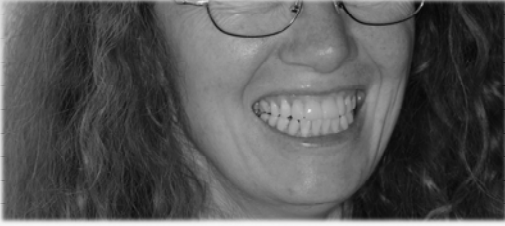© Belsler

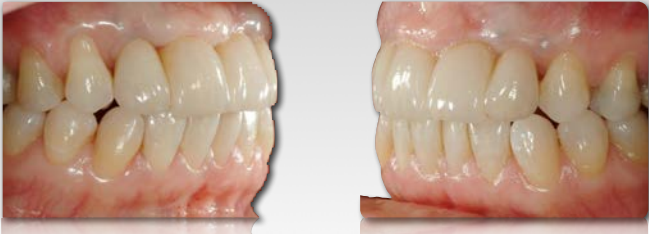

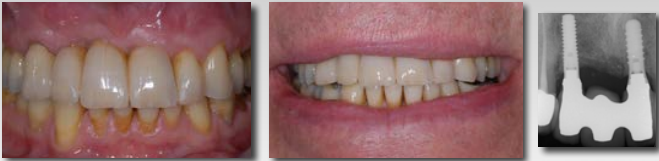© Belsler

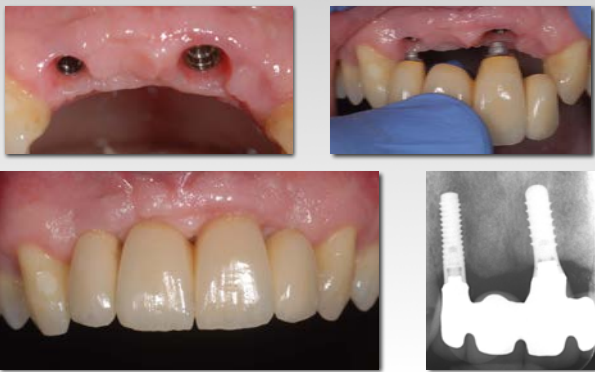


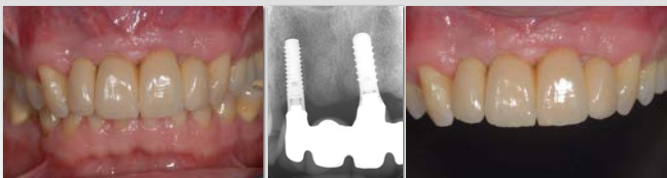
© Belsler











1-year follow-up









